

## Duodenum-preserving pancreatic head resection (DPPHR) in chronic pancreatitis: its rationale and results

FUMIAKI OZAWA, HELMUT FRIESS, YASUO KONDO, SHAILESH V. SHRIKHANDE, and MARKUS W. BÜCHLER

Department of Visceral and Transplantation Surgery, University of Bern, Inselspital, CH-3010 Bern, Switzerland

**Abstract** Persistent, uncontrolled pain is the most common indication for surgery in chronic pancreatitis. In the presence of an inflammatory mass in the pancreatic head or in pancreatic head-related complications of chronic pancreatitis, resection procedures are inevitable. The Whipple procedure, originally introduced for malignant lesions of the periampullary region, is commonly employed, although it represents surgical over-treatment in a benign pancreatic disorder. In this article, we discuss our long experience with duodenum-preserving pancreatic head resection (Beger procedure) for chronic pancreatitis. Prospective, randomized controlled trials suggest that this organ- and function-preserving procedure should be the gold standard for the surgical treatment of pancreatic head-related complications of chronic pancreatitis.

**Key words** Chronic pancreatitis · Duodenum-preserving pancreatic head resection · Pain · Organ-preserving surgery

### Rationale for performing duodenum-preserving pancreatic head resection

Duodenum-preserving pancreatic head resection (DPPHR), first performed in 1972 by Hans Beger, was introduced to treat pancreatic head-related complications of chronic pancreatitis (CP).<sup>1–3</sup> The procedure comprises a subtotal resection of the head of the pancreas with preservation of the body and tail of the pancreas, the duodenum, and the stomach. To guarantee a sufficient blood supply to the remaining duodenum, a thin rim of the pancreas dorsal and close to the duodenum is preserved.<sup>4</sup> This procedure safely removes the inflammatory mass in the head of pancreas and thereby leads to decompression and/or drainage of the main pancreatic duct, the common bile duct, the

duodenum, and major retropancreatic vessels, and preserves exocrine and endocrine pancreatic function. This is achieved by avoiding partial resection of the stomach, the duodenum, or the extrahepatic common bile duct, which is the major difference compared with the classical Whipple or the pylorus-preserving Whipple operation.

### Chronic pancreatitis: pain as a leading clinical symptom

Chronic pancreatitis (CP) is a disease of increasing incidence, characterized by a progressive destruction of the exocrine parenchyma as a result of chronic inflammation, and increasing fibrosis, which is associated with recurrent attacks of intractable pain and increasing degrees of exocrine and endocrine insufficiency. Treatment of chronic pancreatitis is often a matter of controversial debate between surgeons and gastroenterologists. Because surgical techniques have steadily improved and perioperative morbidity and mortality have consistently declined over the years, the indications for surgery are no longer limited by surgical shortcomings and reservations based on surgical morbidity and mortality.

Severe upper abdominal pain is one of the dominant clinical symptoms of CP, and is probably the single most important reason for the treatment of CP patients. Unfortunately, the pain often does not respond to analgesics,<sup>5–8</sup> and is noted to persist in 85% and 55% of conservatively managed patients 5 and 10 years after diagnosis, respectively.<sup>9</sup> In the past decade, several hypotheses of pain pathogenesis have been proposed, which continue to be controversially discussed. The duct pressure-pain theory, one commonly suggested hypothesis, proposes that increased intraductal and parenchymal pressures are caused by obstruction or stenosis of the main pancreatic duct. However, many

Offprint requests to: H. Friess

Received: July 3, 2000 / Accepted: August 8, 2000

clinicians question whether this pressure could be the sole cause of abdominal pain in CP. The failure of octreotide treatment, known to potently inhibit exocrine pancreatic secretion, contradicts the pressure-pain theory in many CP patients.<sup>10,11</sup> This goes along with surgical experience that up to 35% of patients with CP who undergo duct drainage operations do not experience significant relief from the excruciating pain.<sup>12</sup> In 1994, we investigated the relationship between pain and pancreatic parenchymal pressure in 12 patients undergoing surgery for CP and found, in contrast to previous reports, that pancreatic parenchymal pressure was not closely related to pain in CP patients.<sup>13</sup> The development of refined molecular biology techniques has allowed us to study the pathogenesis of pain mechanisms at the cellular level. Recent studies have revealed that direct damage of intrapancreatic nerves and the interaction of nerves and inflammatory cells is associated with pain (neuro-immune interaction theory).<sup>14-16</sup> Furthermore, a significantly greater diameter and density of nerves, in combination with destruction of their perineurium, a concomitant increase of growth-associated protein 43 (GAP-43) and of pain-transmitting neuropeptides such as substance P and calcitonin-gene-related peptide (CGRP) in the intrinsic neurons, and enlarged nerve fibers have been described in CP.<sup>15,17</sup> The morphological changes in pancreatic nerves are associated with enhanced expression of nerve growth factor (NGF) and its receptor TrkA, suggesting that these factors promote nerve proliferation and also contribute to pain in CP patients.<sup>18</sup> All these findings suggest that intrapancreatic nerves are growing actively in CP and that combination of various neural alterations may contribute significantly to the generation of pain in chronic pancreatitis.

### Indications for surgery in chronic pancreatitis

Surgical intervention is mandated if persistent pain cannot be adequately controlled by analgesics and when complications such as common bile duct obstruction, pancreatic duct obstruction, duodenal stenosis, and involvement of major retropancreatic intestinal vessels occur in the neighboring organs.<sup>19,20</sup> Also, the suspicion of pancreatic cancer is a definite indication for surgery in CP patients. Recently, it was reported that surgery could also have a positive influence on the further course of the disease, postponing the final "burn-out" of the pancreas and thereby the appearance of exocrine and endocrine insufficiency.<sup>21</sup> Because as many as 50% of all patients with CP ultimately require surgical treatment,<sup>22-24</sup> the type of operative procedure and its long-term results are important points that need to be addressed when treatment strategies are evaluated for these patients.<sup>4</sup>

### Options for surgical treatment for chronic pancreatitis

Surgical treatment of CP is broadly divided into drainage procedures and resection procedures. Drainage operations, such as longitudinal pancreaticojejunostomy (Partington-Rochelle),<sup>25</sup> should always be considered first because they do not lead to postoperative exocrine and endocrine insufficiency. However, there are very few specific indications for drainage procedures in CP which lead to satisfying long-term results. A dilation of the main pancreatic duct greater than 7 mm with obstruction in the pancreatic head in the absence of pancreatic head enlargement by an inflammatory mass is an ideal indication for performing a Partington-Rochelle procedure.<sup>26</sup> If drainage procedures are used without adherence to specific criteria, the long-term results are frequently disappointing.<sup>26</sup> If an inflammatory mass is present at any location in the pancreas, a resection procedure is indicated.

The Whipple procedure, proposed by Kausch in 1912<sup>27</sup> and brought into use with various modifications by Whipple et al. in 1935,<sup>28</sup> was originally developed to treat malignant disease in the periampullary region. Later in the century, as safety improved, this procedure was also adopted for the treatment of benign pancreatic disorders, including chronic pancreatitis. Over the years, the Whipple procedure has become progressively safer, and current reports in experienced centers with adequate patient load show a hospital mortality under 5%.<sup>29-31</sup> Until recently, the procedure served as the standard operation for an inflammatory mass in the pancreatic head in CP patients. However, there appears to be little justification to treat a benign pancreatic disease with a radical oncological operation that includes the removal of peripancreatic organs, which are only secondarily involved in the disease. This fact led to the development of organ-preserving procedures specifically used to treat complications of chronic pancreatitis.

The pylorus-preserving Whipple resection was originally introduced to treat malignant pancreatic head and periampullary tumors, and represents a more organ-preserving alternative to the classical Whipple operation.<sup>32</sup> This surgical technique was established by Watson in 1944<sup>32</sup> and re-introduced in clinical practice by Traverso and Longmire in 1978.<sup>33</sup> Nowadays it is popularized as an alternative to the classical Whipple resection. By preserving the stomach, the pylorus, and the first part of the duodenum, the pylorus-preserving Whipple resection offers protection against the postgastrectomy syndrome, including gastric dumping.

Additionally, preservation of the pylorus prevents reflux of bile and pancreatic juice, which can often lead to gastritis and subsequent gastric ulceration. Long-term follow-up studies reveal a substantial deterioration

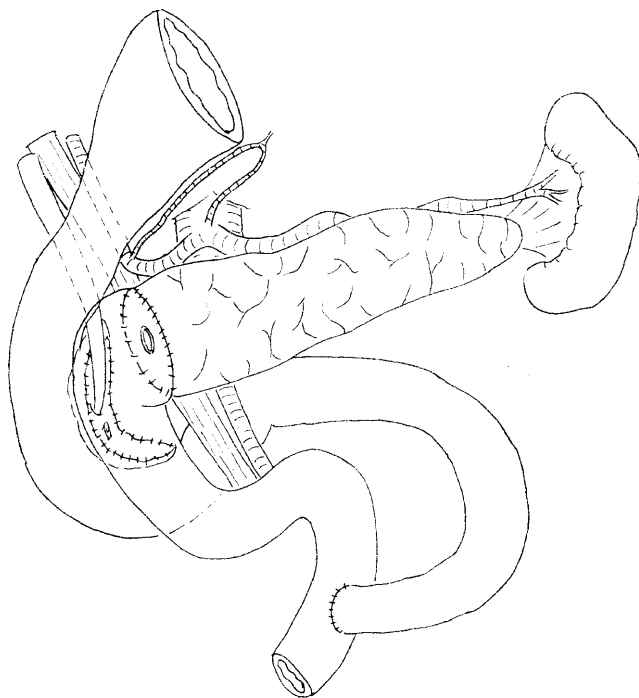
in the exocrine and endocrine pancreatic function. More than one-third of the patients who undergo a pylorus-preserving Whipple resection will need oral pancreatic enzyme supplementation, and nearly 40% of the patients will develop an insulin-dependent diabetes mellitus within the first 5 years of the operation.<sup>34-37</sup> Regarding quality of life, the pylorus-preserving Whipple resection provides satisfying results. There is postoperative weight gain in around 90% of the patients,<sup>35,38</sup> and the operation leads to long-lasting pain relief in 85%–95% of the patients during the first 5 years postoperatively.<sup>35,38,39</sup>

The duodenum-preserving pancreatic head resection (DPPHR) was first performed in 1972 by Hans Beger to specifically treat the pancreatic head-related complications of patients with CP; the operation extended to other organs neighboring the pancreas which were secondarily involved by the disease.<sup>1-3</sup> The procedure was based on the observation that duct drainage procedures are often not sufficient in the treatment of CP with persistent pain — especially in patients with pancreatic head enlargement, who commonly present with pancreatic head-related complications — and that the Whipple procedure, and even the pylorus-preserving Whipple, is an oncological operation which represents surgical over-treatment of a benign disease. In duodenum-preserving pancreatic head resection, the pancreatic head is resected subtotally while preserving the body and tail of the pancreas, the duodenum, the stomach, and the extrahepatic bile duct. In comparison to the classical and pylorus-preserving Whipple procedures, DPPHR offers the major advantage of preserving normal bilio-duodenal anatomy, including ampulla of Vater function and a normal upper digestive route, allowing normal food passage. Delayed gastric emptying, observed in patients after the pylorus-preserving Whipple operation, is not reported after DPPHR.<sup>40</sup> Furthermore, DPPHR is associated with a low incidence of surgically induced diabetes mellitus.<sup>41</sup> This is not surprising, because the central role played by the duodenum in the enteroinsular axis — providing for an adequate insulin release — has been clearly highlighted in experimental animal studies, in healthy subjects, and in CP patients.<sup>42-44</sup> Regarding exocrine pancreatic function, Klempa et al.<sup>45</sup> reported less deterioration after DPPHR than after the classical Whipple procedure, and stated that this is one of the major advantages of conserving the stomach and the duodenum, which might be related to the higher postoperative secretion of hormones such as cholecystokinin (CCK). Our own prospective, controlled, randomized study demonstrated that CCK release was decreased to a greater extent in patients 10 days after the pylorus-preserving Whipple operation than in patients 10 days after DPPHR. In this context, functional causes of neuroendocrine dysre-

gulation, such as denervation of the remaining gland during the surgical procedure, cannot be ruled out. The complexity of the neuro-humoral regulation of digestion and absorption and physiological passage are best preserved by a DPPHR.<sup>46</sup> The guiding principle of this modern operation is to specifically treat and remove only the inflamed portions of the pancreatic head. Consequently, the left part of the pancreas is mostly preserved and there is generally no major restriction of pancreatic exocrine and endocrine function.

### **Duodenum-preserving pancreatic head resection (DPPHR): surgical technique**

The operative technique of a DPPHR consists of three phases: first, after a midline laparotomy, wide exposure of the pancreas is obtained by opening the gastrocolic ligament. Then the duodenum and the pancreatic head are mobilized by a wide Kocherization. Following this, the pancreatic neck is dissected by tunneling under the pancreas, and the neck of the pancreas is gently lifted up, away from the portal vein/superior mesenteric vein, taking care to avoid injury to these major retropancreatic vessels and smaller side branches. In the second phase, multiple stay sutures (with Novafil/PDS 3/0 or 4/0, Davis and Geck; Ethicon, Johnson and Johnson) are made in the pancreatic parenchyma, all along the periphery of the pancreatic head. Besides providing excellent hemostasis during subtotal resection of the pancreatic head, they also serve as reference points for the resection. This avoids inadvertent injury to the C-loop of the duodenum and ensures that a cuff of pancreatic parenchyma (5 mm, to a maximum of 10 mm) along this loop of the duodenum is left behind. The resection of the pancreatic head begins with transection over the portal vein. The pancreatic head is resected subtotally from the right border of the portal vein towards the prepapillary common bile duct. Following subtotal resection of the pancreatic head, meticulous hemostasis of the left pancreas is ensured. Lastly, the creation of a Roux-en-Y loop of the jejunum is followed by an end-to-side or an end-to-end pancreatico-jejunal anastomosis, while another side-to-side reconstruction is performed between the remaining pancreatic head along the duodenum and the interposed jejunal loop (Fig. 1). The anastomoses are always performed in two layers. We prefer to use PDS 4/0 or 5/0 as suture material. In instances of stenosis of the common bile duct in the intrapancreatic segment, which cannot be decompressed by resection of the surrounding pancreatic head, or if the common bile duct is accidentally opened during subtotal pancreatic head resection, an additional biliary anastomosis can easily be performed. This modification is always combined with a cholecystec-



**Fig. 1.** Duodenum-preserving pancreatic head resection, according to Beger<sup>2</sup>

tomy. In patients with multiple stenoses and dilatations in the left-side main pancreatic duct, a longitudinal incision of the main duct can be performed with reconstruction by a side-to-side pancreatico-jejunoanastomosis, similar to a Puestow operation.

### Postoperative results following surgery in chronic pancreatitis

#### *Early and late results following DPPHR*

In our series of 298 patients<sup>4</sup> who underwent a DPPHR, the patient population was 84% male (mean age, 44 years; range, 22 to 74 years) and 89% of the total group were alcohol abusers. Abdominal pain (94%), inflammatory enlargement of the pancreatic head (83%), common bile duct stenosis (48%), and pancreatic duct obstruction (62%) were the predominant indications for surgery. Additionally, compression of the peripancreatic vessels (17%) and some degree of duodenal stenosis (32%) were found. Pronounced macromorphological alterations in the pancreatic head were usually seen, with the development of small pseudocysts, necrosis, and pancreatic stones. Preoperatively, 52% of our patients had normal blood glucose levels, whereas 23% and 25% showed signs of subclinical and overt insulin-dependent diabetes mellitus, respectively.

Hospital mortality and morbidity after the DPPHR were 1.01% and 28.5%, respectively. Three patients died in the hospital — one after pulmonary embolism and two from septic shock from leakage of the pancreatic anastomosis. Eighty-five patients (28.5%) had early postoperative complications. Seventeen patients (5.7%) required a relaparotomy because of an anastomotic leakage ( $n = 5$ ), an intra-abdominal abscess ( $n = 3$ ), bleeding ( $n = 3$ ), small-bowel obstruction ( $n = 2$ ), septic shock ( $n = 1$ ), ischemia of the duodenum ( $n = 1$ ), common bile duct stenosis ( $n = 1$ ) and an ulcer perforation ( $n = 1$ ). Thirty-five patients (11.7%) suffered from medical complications such as pulmonary failure, pneumonia, cardiocirculatory failure, and/or renal failure, but all these patients recovered thanks to intensive medical support. Only six patients (2%) developed insulin-dependent diabetes mellitus in the early postoperative period, indicating that the DPPHR preserved endocrine pancreatic function although the major part of the pancreatic head parenchyma was resected. The median duration of postoperative hospitalization was 13 days (range, 7 to 59 days).

Long-term postoperative follow-up was carried out in 232 patients (median, 6 years; range, 1 to 22 years). Three patients died postoperatively, 40 patients were lost to follow-up, and 23 patients (23 of 255 patients; 9%) died within a median follow-up period of 6 years. In the late follow-up period, 62% (143/232) of the patients were pain-free, and 12% (28/232) had frequent episodes of pain. Eighty-one percent (187/232) of the patients experienced an increase in body weight after surgery. The professional rehabilitation rate was 63% (147/232). Eleven patients (5%) were unemployed and 74 patients (32%) had retired either because of age or because of the disease. Only 2.6% of patients (6/232) suffered from newly developed and therefore operation-induced insulin-dependent diabetes mellitus (Table 1).

In 1999, quality of life was evaluated in a series of 303 patients with DPPHR,<sup>47</sup> using a Karnofsky index, which is a reliable and validated quality-of-life measure consisting of a ten-point incremental scale from 0 to 100, where the lower the score, the worse the level of independent functioning.<sup>48</sup> A Karnofsky index of 90 to 100 was found in 72% of the patients; an index of 80–90 was found in 10%, and in 18% of the patients the index was less than 80.

#### *Comparison of DPPHR and pylorus-preserving Whipple: results of a prospective, randomized, unicenter controlled study*

Recently a prospective, randomized, controlled trial was performed to analyze the advantages and disadvantages of two competitive surgical procedures in 40

**Table 1.** Late follow-up results in 232 patients with duodenum-preserving pancreatic head resection (DPPHR)<sup>a</sup>

Pain 88%	None	143/232	62%
	Infrequent <sup>a</sup>	61/232	26%
	Frequent <sup>b</sup>	28/232	12%
Body weight	Increased	187/232	81%
	Weight loss	48/232	22%
Enzyme substitution	Full	42/219	19%
	Half dosage	97/219	44%
	Occasionally	24/219	11%
	None	56/219	26%
Newly developed insulin-dependent diabetes mellitus (early postop)		6/232	2%
Professional rehabilitation	Complete	147/232	63%
	Unemployed	11/232	5%
	Retired <sup>c</sup>	74/232	32%
Rehospitalization		23/232	10%

<sup>a</sup>Pain occurring once a month or less; no need for regular analgesic medication

<sup>b</sup>Pain occurring weekly or daily, requiring analgesic medication

<sup>c</sup>Retired because of advanced age or disease

**Table 2.** Comparison of DPPHR and pylorus-preserving Whipple in patients with chronic pancreatitis<sup>s</sup>

	DPPHR ( <i>n</i> = 20)	Pylorus-preserving Whipple ( <i>n</i> = 20)
Postoperative morbidity		
Stroke	0%	5%
Pancreatic fistula	0%	5%
Bleeding	10%	0%
Pulmonary complications	5%	2%
Relaparotomy	0%	0%
Mortality	0%	0%
Hospital stay (days)	13 (range, 8–21 days)	14 (range, 9–37 days)
Six-month follow-up results		
Pain		
None	75%*	40%*
Infrequent	19%	27%
Frequent	6%	33%
Body weight		
Increased	88%	67%
Weight loss	0%	27%
Average increase	4.1 ± 0.9 kg*	1.9 ± 1.2 kg*
Professional rehabilitation	80%	67%
Rehospitalization	13%	27%

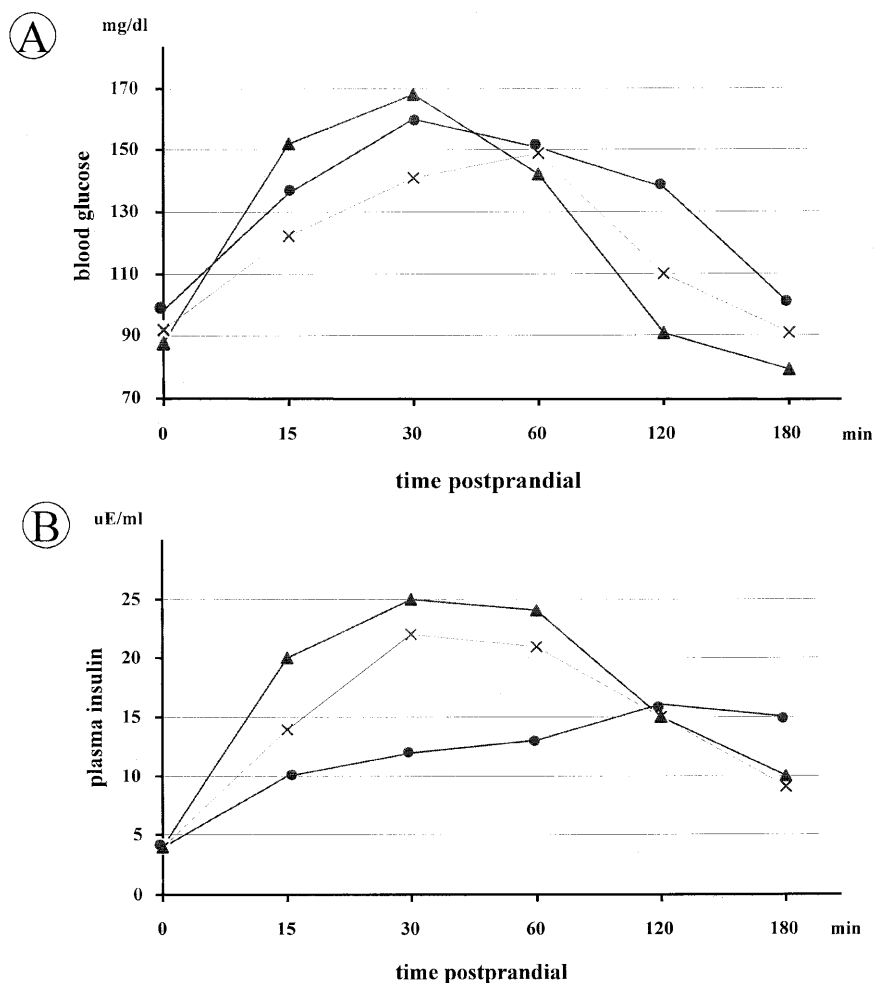
\**P* < 0.05

patients with CP: pylorus-preserving Whipple resection versus DPPHR<sup>8,49</sup> (Table 2).

The hospital mortality rate was zero and no relaparotomy was necessary in either procedure. Short-term postoperative morbidity was 20% in the pylorus-preserving Whipple group and 15% in the DPPHR group. In a 6-month follow-up, it was possible to include 19 of 20 patients with DPPHR and 17 of 20 patients with pylorus-preserving Whipple. The lower incidence of recurrent pain after 6 months in the DPPHR group (6%

versus 33% in the pylorus-preserving Whipple group) complements the two groups' data for rehospitalization (13% in the DPPHR group versus 27% in the pylorus-preserving Whipple group), professional rehabilitation (80% in the DPPHR group versus 67% in the pylorus-preserving Whipple group), and body weight gain (4.1 ± 0.9 kg in the DPPHR group versus 1.9 ± 1.2 kg in the pylorus-preserving Whipple group).

Preoperatively, blood glucose and insulin levels following a standard test meal were comparable in pa-



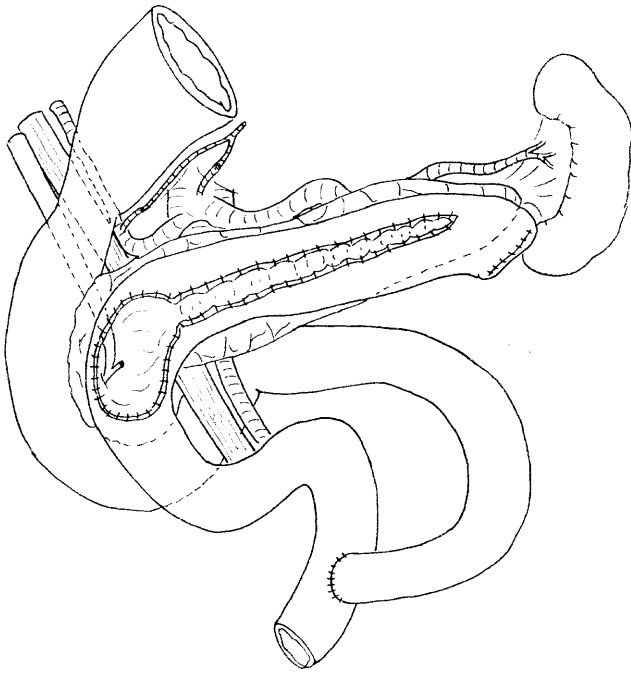
**Fig. 2A,B.** Comparison of duodenum-preserving pancreatic head resection (DPPHR) and pylorus-preserving Whipple in terms of **A** blood glucose level and **B** plasma insulin level. Preoperative levels in the DPPHR group and the pylorus-preserving Whipple group (*crosses*). Postoperative (after 6 months) levels in the DPPHR group (*triangles*) and in the pylorus-preserving Whipple group (*closed circles*)

tients randomized to either type of resection. After 6 months, patients in the pylorus-preserving Whipple group revealed a pathologic glucose tolerance (Fig. 2A). After 120 min, their median blood glucose tolerance level was 139 mg/dl, while that of the DPPHR group was normal, at 90 mg/dl ( $P < 0.01$ ). The median area under the curve was 25.3 mg/dl per min (lower quartile, 18; upper quartile, 31) in the pylorus-preserving Whipple group and 20.5 mg/dl per min (lower quartile, 17; upper quartile, 35) in the DPPHR group ( $P < 0.05$ ). Preoperative insulin secretion was comparable in both groups. The insulin secretion capacity in the pylorus-preserving Whipple group decreased during the first 6 postoperative months, from 29.5  $\mu$ E/ml per min to 24.5  $\mu$ E/ml per min. In patients who underwent the DPPHR, the insulin secretion capacity increased from 29.4  $\mu$ E/ml per min to 32.1  $\mu$ E/ml per min. The area under the curve after 6 months was significantly different in the two groups (Fig. 2B). These results demonstrated that patients who underwent DPPHR had a better glucose tolerance and a higher insulin secretion

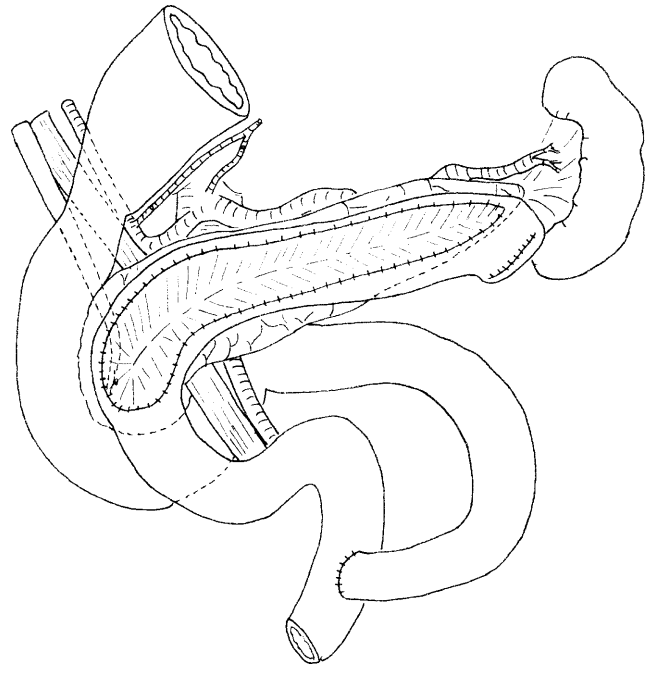
capacity postoperatively than patients who underwent a pylorus-preserving Whipple resection.

#### *Surgical modifications of DPPHR*

As a modification of the Beger procedure, in 1987 Frey and Smith<sup>50</sup> introduced longitudinal pancreaticojejunostomy in combination with a local pancreatic head resection without dividing the pancreas above the portal vein (Fig. 3). The concept of the Frey operation is to drain the pancreas up to the second duct branches and to emphasize the importance of freeing up the common bile duct. Moreover, Frey and Smith noted that, with this procedure, the common bile duct could often be freed from the structures compressing it within the pancreatic segment, avoiding the necessity of performing a separate biliary bypass. According to a prospective study<sup>51</sup> comparing DPPHR (20 patients) and the Frey procedure (22 patients), postoperative pain relief and maintenance of exocrine and endocrine pancreatic function were favorable in both groups, and there was



**Fig. 3.** Modification of the duodenum-preserving pancreatic head resection, according to Frey and Smith<sup>50</sup>

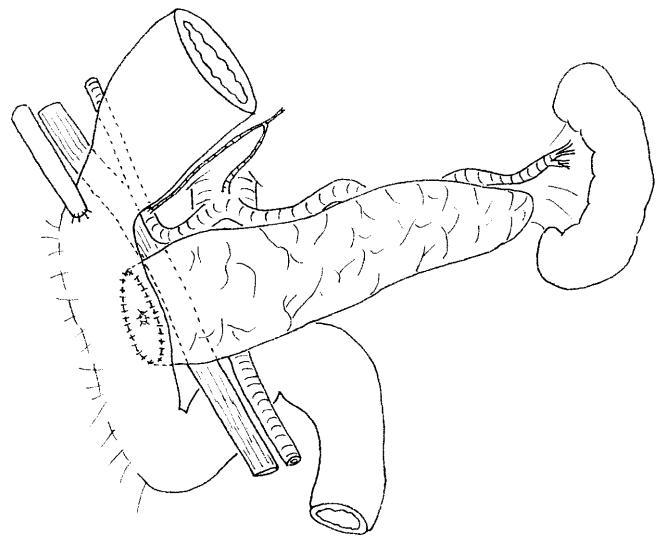


**Fig. 4.** Modification of the duodenum-preserving pancreatic head resection in patients with small pancreatic duct disease, according to Izbicki et al.<sup>52</sup>

no significant difference between the two groups. The total relief of symptoms, the global quality-of-life and working scores also did not differ significantly. However, these findings are not surprising, simply, because in experienced hands, the Frey procedure increasingly appears to be just a modification of the DPPHR and its described modifications rather than a new surgical principle.

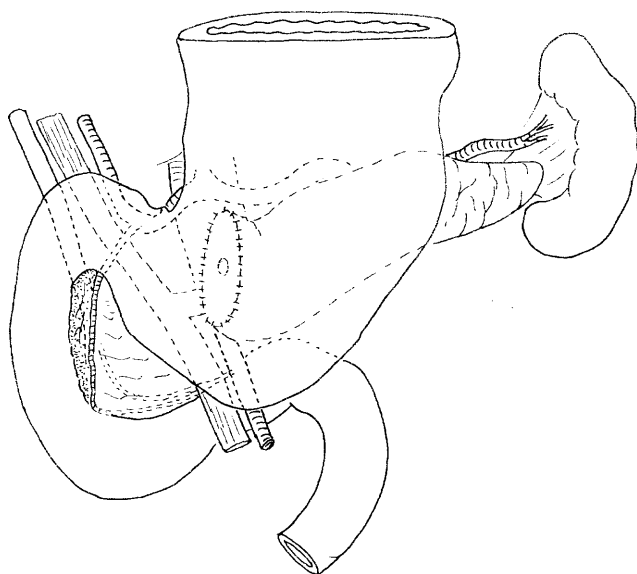
Recently Izbicki and coworkers<sup>52</sup> attempted to modify the Frey procedure to also treat the so-called small main pancreatic duct forms (main pancreatic duct size, less than 3 mm) of CP with a combination of duct drainage and local resection, comprising a longitudinal V-shaped excision of the ventral pancreas with subsequent drainage of secondary and tertiary ductal branches by a longitudinal pancreatico-jejunostomy (Fig. 4). The first results of a small patient population ( $n = 13$ ) with a median follow-up time of 30 months appear promising. There was permanent pain relief and significant improvement in quality of life, and this procedure could be performed without mortality and with low morbidity (15.4%).<sup>52</sup>

In 1990, Imaizumi and co-workers<sup>53</sup> introduced the duodenum-preserving total pancreatic head resection with pancreaticoduodenostomy and choledochoduodenostomy. The interesting feature of this procedure is complete resection of the pancreatic head and a more physiological reconstruction. After resection of the pancreatic head, the blood supply to the duodenum de-



**Fig. 5.** Modification of the duodenum-preserving pancreatic head resection, according to Imaizumi et al.<sup>53</sup>

pends upon intramural blood flow. The blood supply to the distal duodenum is maintained by preserving the branches from the inferior pancreaticoduodenal artery or mesoduodenal vessels. Because a Kocher mobilization is not performed in this approach, branches of the portal vein are drained into the retroperitoneum. The reconstruction in this procedure is characterized by an end-to-side anastomosis of the residual pancreatic duct



**Fig. 6.** Modification of the duodenum-preserving pancreatic head resection, according to Kimura et al.<sup>54,55</sup>

and the common bile duct to the C-loop of the preserved duodenum (Fig. 5). After this reconstruction, the bile and pancreatic juice are physiologically mixed with the food in the duodenum and a blind loop does not exist. The effectiveness of this procedure has not yet been evaluated, since the number of patients who underwent this procedure was not high enough for systematic analysis.<sup>53</sup>

Based on an anatomical study on autopsy materials, in 1996 Kimura and coworkers<sup>54,55</sup> also proposed a modification of the DPPHR. Their reports described duodenum-preserving subtotal pancreatic head resection, performed in a patient with a mucin-producing pancreatic tumor, followed by a pancreatico-gastric anastomosis. A small part of the pancreatic head — between the duodenum, the anterior superior pancreaticoduodenal artery, and the common bile duct — was not removed, because the artery which supplies the ampulla of Vater runs in this region.<sup>55</sup> The connective tissue membrane of the posterior surface of the pancreas was carefully kept intact to preserve the pancreaticoduodenal arteries and veins (Fig. 6).

## Conclusions

Duodenum-preserving pancreatic head resection was initially performed to treat pancreatic head-related complications in patients with chronic pancreatitis. It was based on the experience that pancreatic duct drainage procedures often do not relieve pain over the long term and that the Whipple procedure and its

variations, including the pylorus-preserving Whipple, are oncological operations which constitute surgical overtreatment for a benign pancreatic disease. The effectiveness of duodenum-preserving pancreatic head resection has been evaluated in several studies. With regard to pain relief, postoperative mortality and morbidity, weight gain, professional rehabilitation, re-hospitalization, and preservation of endocrine and exocrine pancreatic function, the duodenum-preserving pancreatic head resection demonstrates a clear advantage over other surgical and interventional options. Furthermore, duodenum-preserving pancreatic head resection is an operation which incorporates the novel knowledge of the pathophysiological mechanisms responsible for the inflammatory process, pain generation, and glucose metabolism. We therefore firmly believe that this modern operation should be considered as the future standard in the management of chronic pancreatitis, especially when the main lesion is located in the pancreatic head.

The specific indications of this operation for pancreatic head-related complications in patients with chronic pancreatitis, as well as in patients with other pancreatic disorders, have not been settled. Benign peripancreatic lesions — including benign tumors, anomalous junctions of the pancreatico-biliary ductal system, malformation of the main pancreatic duct, and cystic lesions of the pancreatic head — may also be good indications for this procedure. However, caution must be exercised in malignant lesions, even when they appear to be low grade.

## References

1. Beger HG, Büchler M, Bittner R, Uhl W (1990) Duodenum-preserving resection of the head of the pancreas — an alternative to Whipple's procedure in chronic pancreatitis. *Hepatogastroenterology* 37:283–289
2. Beger HG, Witte C, Kraas E, Bittner R (1980) Erfahrung mit einer das Duodenum erhaltenden Pankreaskopfresektion bei chronischer Pankreatitis. *Chirurg* 51:303–309
3. Beger HG, Büchler M, Bittner RR, Oettinger W, Roscher R (1989) Duodenum-preserving resection of the head of the pancreas in severe chronic pancreatitis. *Ann Surg* 209:273–278
4. Büchler MW, Friess H, Bittner R, Roscher R, Krautzberger W, Müller MW, Malferteiner P, Beger HG (1997) Duodenum-preserving pancreatic head resection: long-term results. *J Gastrointest Surg* 1:13–19
5. DiMagno EP (1993) A short, eclectic history of exocrine pancreatic insufficiency and chronic pancreatitis. *Gastroenterology* 104:1255–1262
6. Beger HG, Krautzberger W, Bittner R, Büchler M (1985) Duodenum-preserving resection of the head of the pancreas in patient with severe chronic pancreatitis. *Surgery* 97:467–473
7. Friess H, Müller M, Ebert M, Büchler MW (1995) Chronic pancreatitis with inflammatory enlargement of the pancreatic head. *Zentralblatt für Chirurgie* 120:292–297
8. Büchler MW, Friess H, Müller MW, Wheatley AM, Beger HG (1995) Randomized trial of duodenum-preserving pancreatic



- head resection versus pylorus-preserving Whipple in chronic pancreatitis. *Am J Surg* 169:65–69
9. Lankisch PG, Lohr-Happe A, Otto J, Creutzfeldt W (1993) Natural course in chronic pancreatitis. Pain, exocrine and endocrine pancreatic insufficiency and prognosis of the disease. *Digestion* 54:148–155
  10. DiMango EP, Layer P, Clain JE (1993) Chronic pancreatitis. In: Go VLW, DiMango EP, Gardner JD, Lebenthal E, Reber HA, Scheele GA (eds) *The pancreas*. Raven, New York, pp 707–740
  11. DiMango EP (1993) Conservative management of chronic pancreatitis. In: Beger HG, Büchler M, Malfertheiner P (eds) *Standards in pancreatic surgery*. Springer, New York Berlin Heidelberg Tokyo, pp 325–331
  12. Prinz RA, Greenlee HB (1990) Pancreatic duct drainage in chronic pancreatitis. *Hepatogastroenterology* 37:295–300
  13. Manes G, Büchler M, Pieramico O, Di Sebastiano P, Malfertheiner P (1994) Is increased pancreatic pressure related to pain in chronic pancreatitis? *Int J Pancreatol* 15:113–117
  14. Keith RG, Keshavjee SH, Kerenyi NR (1985) Neuropathology of chronic pancreatitis in humans. *Can J Surg* 28:207–211
  15. Bockman DE, Büchler M, Malfertheiner P, Beger HG (1988) Analysis of nerves in chronic pancreatitis. *Gastroenterology* 94:1459–1469
  16. Büchler M, Weihe E, Friess H, Malfertheiner P, Bockman E, Müller S, Nohr D, Beger HG (1992) Changes in peptidergic innervation in chronic pancreatitis. *Pancreas* 7:183–192
  17. Weihe E, Nohr D, Müller S, Büchler M, Friess H, Zentel HJ (1991) The tachykinin neuroimmune connection in inflammatory pain. *Ann NY Acad Sci* 632:283–295
  18. Friess H, Zhu ZW, di Mola FF, Kulli C, Graber HU, Andren-Sandberg A, Zimmermann A, Korc M, Reinshagen M, Büchler MW (1999) Nerve growth factor and its high-affinity receptor in chronic pancreatitis. *Ann Surg* 230:615–624
  19. Manes G, Pieramico O, Uomo G (1992) Pain in chronic pancreatitis: recent pathogenetic findings. *Minerva Gastroenterol Dietol* 38:137–143
  20. Gullo L, Barbara L (1991) Treatment of pancreatic pseudocysts with octreotide. *Lancet* 338:540–541
  21. Nealon WH, Townsend CM Jr, Thompson JC (1988) Operative drainage of the pancreatic duct delays functional impairment in patients with chronic pancreatitis. A prospective analysis. *Ann Surg* 208:321–329
  22. Ammann RW, Akovbiantz A, Largiader F, Schueler G (1984) Course and outcome of chronic pancreatitis. Longitudinal study of a mixed medical-surgical series of 245 patients. *Gastroenterology* 86:820–828
  23. Ammann RW (1994) Natural history of chronic pancreatitis. *Dig Surg* 11:267–274
  24. Steer ML, Waxman I, Freedman S (1995) Chronic pancreatitis. *N Engl J Med* 332:1482–1490
  25. Partington PF, Rochelle REL (1960) Modified Puestow procedure for retrograde drainage of the pancreatic duct. *Ann Surg* 152:1037–1043
  26. Rios GA, Adams DB, Yeoh KG, Tarnasky PR, Cunningham JT, Hawes RH (1998) Outcome of lateral pancreaticojejunostomy in the management of chronic pancreatitis with nondilated pancreatic ducts. *J Gastrointest Surg* 2:223–229
  27. Kausch W (1912) Das Carcinom der Papilla Duodeni und seine radikale Entfernung. *Beitr Klin Chir* 78:439–486
  28. Whipple AO, Pearson WB, Mullins CR (1935) Treatment of carcinoma of the ampulla of Vater. *Ann Surg* 102:763–769
  29. Crist DW, Sitzmann JV, Cameron JL (1987) Improved hospital morbidity, mortality and survival after the Whipple procedure. *Ann Surg* 206:358–365
  30. Grace PA, Pitt HA, Tompkins RK, DenBesten L, Longmire WP Jr (1986) Decreased morbidity and mortality after pancreatoduodenectomy. *Am J Surg* 151:141–149
  31. Trede M (1985) The surgical treatment of pancreatic carcinoma. *Surgery* 97:28–35
  32. Watson K (1944) Carcinoma of the ampulla of Vater: successful radical resection. *Br J Surg* 31:368–373
  33. Traverso LW, Longmire WP (1978) Preservation of the pylorus in pancreaticoduodenectomy. *Surg Gynecol Obstet* 146:959–962
  34. Hunt DR, McLean R (1989) Pylorus-preserving pancreatotomy: functional results. *Br J Surg* 76:173–176
  35. Martin RF, Rossi RL, Leslie KA (1995) Long-term results of pylorus-preserving pancreatoduodenectomy for chronic pancreatitis. Presentation at 29th annual meeting of the Pancreas Club, San Diego
  36. Rossi RL, Rothschild J, Braasch JW, Munson JL, ReMine SG (1987) Pancreatoduodenectomy in the management of chronic pancreatitis. *Arch Surg* 122:416–420
  37. Braasch JW, Rossi RL, Watkins E Jr, Deziel DJ, Winter PF (1986) Pyloric and gastric-preserving pancreatic resection. *Ann Surg* 206:411–418
  38. Morel P, Rohner A (1992) The pylorus-preserving technique in duodenopancreatectomy. *Surg Annu* 24:89–105
  39. Traverso LW, Kozarek RA (1993) The Whipple procedure for severe complications of chronic pancreatitis. *Arch Surg* 128:1047–1053
  40. Müller MW, Friess H, Beger HG, Kleeff J, Lauterburg B, Glasbrenner B, Riepl RL, Büchler MW (1997) Gastric emptying following pylorus-preserving Whipple and duodenum-preserving pancreatic head resection in patients with chronic pancreatitis. *Am J Surg* 173:257–263
  41. Schwarz A, Schlosser W, Schoenberg MH, Beger HG (1999) Is a Whipple operation in chronic pancreatitis still a current procedure? *Z Gastroenterol* 37:241–248
  42. Malfertheiner P, Sarr MG, Nelson DK, DiMango EP (1994) Role of the duodenum in postprandial release of pancreatic and gastrointestinal hormones. *Pancreas* 9:13–19
  43. Bittner R, Butters M, Büchler M, Nägele S, Roscher R, Beger HG (1994) Glucose homeostasis and endocrine pancreatic function in patients with chronic pancreatitis before and after surgical therapy. *Pancreas* 9:47–53
  44. Creutzfeldt W, Eber R (1986) The enteroinsular axis. In: Go VLW (ed) *The exocrine pancreas*. Raven New York, pp 333–346
  45. Klempa J, Spatny M, Menzel J, Baca I, Nustede R, Stöckmann F, Arnold W (1995) Pankreasfunktion und Lebensqualität nach Pankreaskopfresektion bei der chronischen Pankreatitis. *Chirurg* 66:350–359
  46. Nicoll CG, Polak JM, Bloom SR (1985) The humoral regulation of food intake, digestion, and absorption. *Ann Rev Nutr* 5:213–239
  47. Beger HG, Schlosser W, Friess H, Büchler MW (1999) Duodenum-preserving pancreatic head resection in chronic pancreatitis changes the natural course of the disease: a single-center 26-year experience. *Ann Surg* 230:512–519
  48. Karnofsky DA, Abelman WH, Craver LF, Burchenal JH (1948) The use of the nitrogen mustards in the palliative treatment of carcinomas. *Cancer* 1:634–656
  49. Friess H, Müller MW, Büchler MW (1994) Duodenum-preserving resection of the head of the pancreas: the future. *Dig Surg* 11:318–324
  50. Frey CF, Smith GJ (1987) Description and rationale of a new operation for chronic pancreatitis. *Pancreas* 2:701–707
  51. Izbicki JR, Bloechle C, Knoefel WT, Kuechler T, Binmoeller KF, Broelsch CE (1995) Duodenum-preserving resection of the head of the pancreas in chronic pancreatitis. A prospective, randomized trial. *Ann Surg* 221:350–358
  52. Izbicki JR, Bloechle C, Broering DC, Kuechler T, Broelsch CE (1998) Longitudinal V-shaped excision of the ventral pancreas for small duct disease in severe chronic pancreatitis: prospective evaluation of a new surgical procedure. *Ann Surg* 227:213–219

53. Imaizumi T, Hanyu F, Suzuki M (1990) A new procedure: duodenum-preserving total resection of the head of the pancreas with pancreaticocholecho-oduodenostomy. *J Bil Tract Pancreas* 11:621–626
54. Kimura W, Morikane K, Futakawa N, Shinkai H, Han I, Inoue T, Muto T, Nagai H (1996) A new method of duodenum-preserving subtotal resection of the head of the pancreas based on the surgical anatomy. *Hepatogastroenterology* 43:463–472
55. Kimura W, Muto T, Makuuchi M, Nagai H (1996) Subtotal resection of the head of the pancreas preserving duodenum and vessels of pancreatic arcade. *Hepatogastroenterology* 43:1438–1441